



**PATIENT**

Lluvia Camarena

**SPECIES**

Canine

**BREED**

Husky Mix

**SEX**

Female Spayed

**AGE**

2.2 years

**WEIGHT**

65.6lbs

**INTERPRETED BY**

Maggie Machen Lamy,  
DVM, DACVIM  
(Cardiology)

**IMAGING PERFORMED BY**

Potomac Mobile  
Veterinary Ultrasound

**HOSPITAL NAME**

Banfield Pet Hospital

**REFERRING VET**

Dr. Jarrett

**INVOICE**

24019

**DATE**

5/4/22

**PRESENTING CLINICAL SIGNS**

History: Prior heart murmur and elevated BNP. Stopped grain-free diet. No murmur ausculted today.

**ECHOCARDIOGRAM FINDINGS**

2D, m-mode, color flow and doppler imaging is available. Normal mitral valve leaflets with no prolapse into the left atrial lumen. No obvious mitral regurgitation with normal left atrial dimension. Normal LV dimension with mildly depressed myocardial function. The tricuspid valve appears normal with trace tricuspid regurgitation. Normal right atrial and ventricular diameter and morphology indicating no overt evidence of pulmonary arterial hypertension. The pulmonic and aortic valves are normal in morphology and mobility. Normal pulmonic and mildly elevated aortic outflow velocities with laminar flow. No obvious aortic or pulmonic insufficiency. No pericardial or pleural effusion noted. No obvious cardiac masses.

**CARDIAC CHART**

CANINE CARDIAC PARAMETERS	MR VMAX (m/s)	TR VMAX (m/s)	LA/AO (Boon method)	LA/AO (Heart Base; Swe)	FS (%)	EF (%)	EPSS (cm)
NORMAL PARAMETER	4.5-5.5	<2.7	1.3	<1.6	28-40	40-100	<0.6
PATIENT	NA	NM	1.1	1.4	26	50	NM
CANINE CARDIAC PARAMETERS	HR (BPM)	AV VMAX (m/s)	PV MAX (m/s)	BODY WEIGHT (kg)	LA 2D short axis Base view (cm)	LVIDd Avg; 2D and m-mode short axis (cm)	LVIDs Avg; 2D and m-mode short axis (cm)
NORMAL PARAMETER	50-100	0.7-1.7	0.7-1.6	BELOW	BELOW	BELOW	BELOW
PATIENT	114	1.6	0.9	29.8	2.8	4.2	3.1
*Normal chamber parameters expressed as a mean value (SD)				3	1.27 (5.3)	2.46 (2.46)	1.36 (5.5)
<b>BODY WEIGHT DEPENDENT PARAMETERS</b>				5	1.40 (4.5)	2.74 (5.2)	1.60 (4.7)
<i>*Note: All measurements based upon multi-modal images and methods. An average value is reported.</i>				10	1.50 (3.8)	3.27 (3.5)	2.06 (3.1)
				15	1.83 (2.0)	3.71 (2.4)	2.43 (2.1)
				20	2.02 (1.9)	4.14 (2.2)	2.80 (2.0)
Adapted from June Boon, Veterinary Echocardiography, 1998				25	2.18 (2.4)	4.48 (2.9)	3.10 (2.5)
Rishniw M and Hollis NE, J Vet Intern Med 2000; 14:429-435				30	2.33 (3.3)	4.83 (3.9)	3.39 (3.4)
Hansson et al, Vet Rad and Ultrasound 2002				35	2.48 (4.3)	5.17 (5.0)	3.69 (4.5)
Bonagura et al. Echocardiography: principles of interpretation, Vet Clin North Am 15:1177, 1995				40	2.62 (5.2)	5.48 (6.1)	3.96 (5.4)
				50	2.88 (7.1)	6.07 (8.3)	4.46 (7.4)

**INTERPRETATION OF THE FINDINGS & FURTHER RECOMMENDATIONS**

Overtly normal cardiac dimensions and function. The LV dimensions are normal; however, the systolic function is mildly depressed, this may be indicative of early disease, may be secondary to a reported grain-free diet or may simply be a normal variant. No significant valvular leaks are visualized, and no evidence of pulmonary hypertension. A mildly elevated aortic outflow velocity is noted, which is a benign finding that may cause a soft murmur depending on heart rate and hydration status.

Given the recent evidence of grain free/boutique/exotic ingredient diets leading to DCM in some (but certainly not all) dogs, recommend avoiding atypical diets lifelong in this patient. No obvious



**PATIENT**

Lluvia Camarena

need for taurine supplementation at this time; however, follow up is advised to screen for progression.

**SPECIES**

Canine

No cardiac contraindication for general anesthesia at this time.

**BREED**

Husky Mix

Monitor for development of a heart murmur, cough, labored breathing, exercise intolerance or collapse episodes.

**SEX**

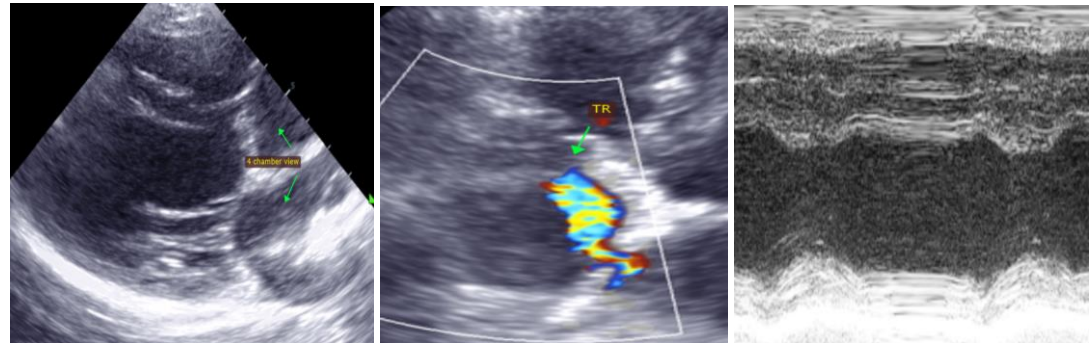
Female Spayed

A recheck echocardiogram is recommended in 12 months, sooner should any signs of cardiac compromise be noted in the interim.

**AGE**

2.2 years

**IMAGES**



**WEIGHT**

65.6lbs

**INTERPRETED BY**

Maggie Machen Lamy,  
DVM, DACVIM  
(Cardiology)

The information and recommendations provided are based on the images presented by the referring veterinarian. No evaluation can be communicated regarding pathology that was not visible in the image/video clips provided.

**IMAGING PERFORMED BY**

Potomac Mobile  
Veterinary Ultrasound

Thank you for this referral. This report was generated using transcription software, and minor dictation errors may be present. If the clinical or image interpretation does not parallel your findings or if I can be of any further assistance, please contact me.

**Maggie Machen Lamy, DVM**  
Diplomate of the American College of Veterinary Internal Medicine (Cardiology)  
info@sonopath.com

**HOSPITAL NAME**

Banfield Pet Hospital

**REFERRING VET**

Dr. Jarrett

**INVOICE**

24019

**DATE**

5/4/22